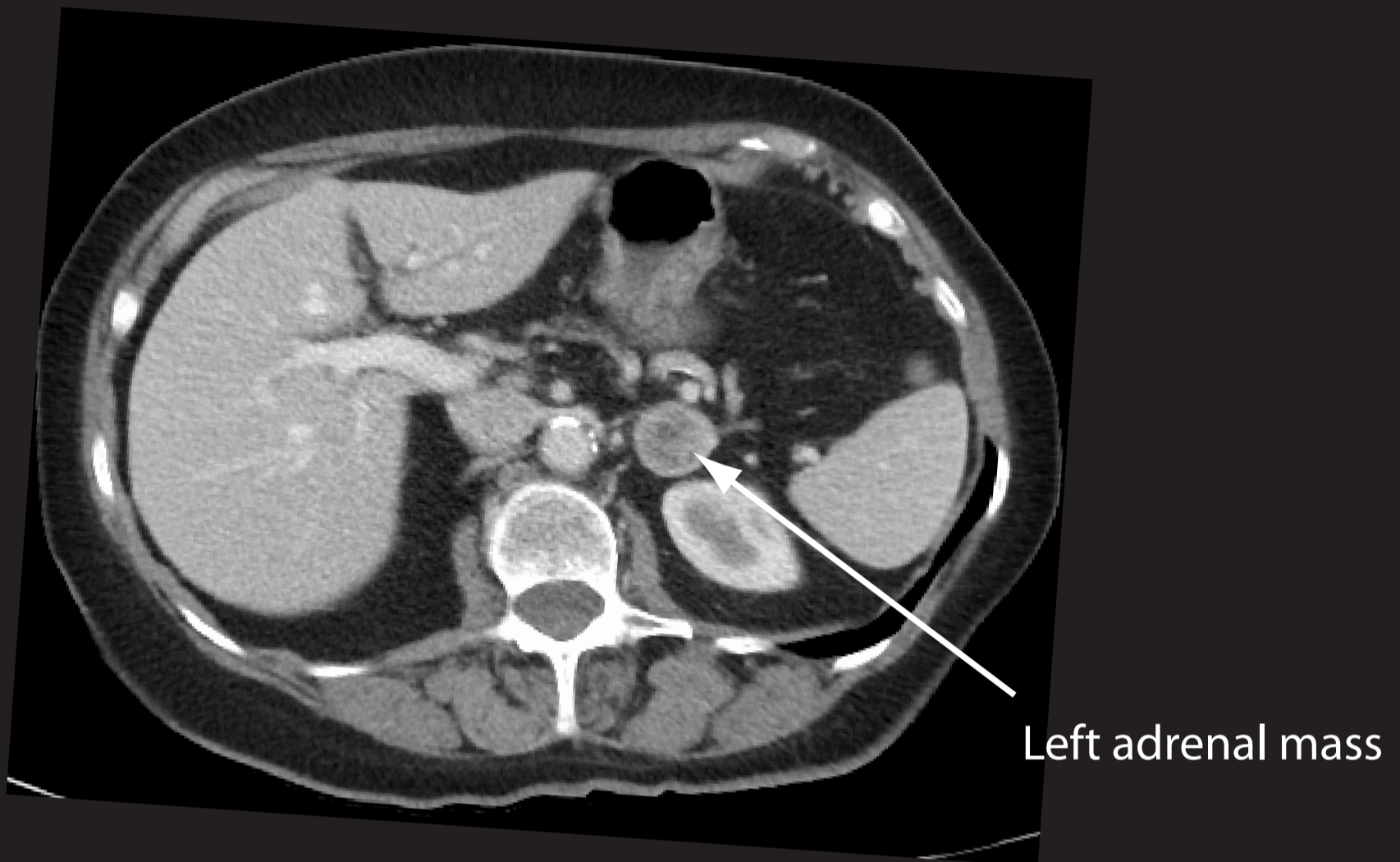


Phaeochromocytoma

This 78 year old hypertensive lady was noted to have a left adrenal tumour on CT colography. Further investigation confirmed raised urinary catecholamines.



MIBG ^{123}I iodine whole body nuclear medicine scans at 4 and 24 hours showing uptake only in the left adrenal gland. There is no evidence of metastases.

